

# Image Quality Test Report

## Spee-D-Mark™ Soft Mark 3D Skin Markers



Zijiao Yang, Physics  
Andrew M. Polemi, PhD, Biomedical Engineering  
Mark B. Williams, PhD, Radiology and Medical Imaging, Biomedical Engineering, and Physics

### Mammographic Skin Marker Selection is Critical to DBT Image Quality

Mammographic skin markers are routinely used in 2D mammography to indicate the locations in the image of known objects such as moles, scars, and palpable lesions. Markers with particular shapes and opacity have been designed to designate particular object types. In all cases the objective is to provide breast radiologists with unambiguous feature identification and minimal distortion or obscuration of breast tissue.

Digital breast tomosynthesis (DBT) acquires a series of low-dose exposures over a limited range of viewing (tube location) angles to permit a 3D image of the breast to be computed. The added depth information provided by DBT permits the breast anatomy to be viewed in thin slices, thereby greatly

reducing the amount of superimposed tissue in the image compared to 2D mammography. The benefits of DBT have been demonstrated in multiple studies with the most commonly cited ones being an increase in the cancer detection rate and reduction of false-positive recall rates (Sharpe et al., 2016). The advent of individual slice viewing via DBT also presents an opportunity for the development of improved skin markers. For example, markers might be designed that are less visible or even invisible in deeper slices, thereby reducing or eliminating obscuration of tissue, and reducing the likelihood that the marker image will sum with the image of normal fibroglandular tissue to create a false positive finding. PDC has developed a skin marker designed for DBT (the Spee-D-Mark™ Soft Mark 3D marker). Here we describe some of the measured imaging properties of the new DBT marker, and compare them with those of a competitor's DBT marker.

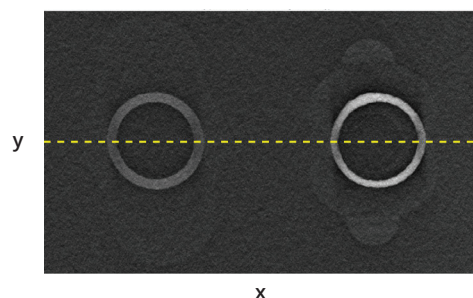
### Image Quality Testing

All DBT scans were performed using a Hologic Dimensions scanner (Hologic, Inc., Marlborough, MA).

**Figure 1** is a slice from a DBT scan of an acrylic block with two skin markers on its top surface. Both markers are marketed for use with DBT. The marker on the left is from PDC, and the one on the right is from a competitor. The slice shown is at the top surface of the block, and clearly shows the markers, as it should.


**Figure 2** is a view perpendicular to the DBT slices, with the z dimension corresponding to depth within the phantom. The slice of Figure 1 is at the top of Figure 2, as indicated by the dotted yellow line. The marker artifacts in Figure 2 that can be seen extending through the slices below the top surface, illustrate one reason that marker selection in DBT is important. These marker artifacts are summed with the images of the breast tissue in the lower slices and can potentially, a) obscure breast tissue and lesions, and b) make tissue with which they are summed artificially bright in the image. These problems can lead to missed abnormalities or perceived abnormalities that do not exist. Compared to markers with conventional x-ray attenuation, such as those used in 2D imaging, markers that are less attenuating (less bright in the image) can minimize these problems in DBT.

x-y Plane View (Left: PDC Right: Competitor)



**Figure 1. Comparison of Markers in Skin Level Slice:** Slice from DBT image showing two skin markers on the surface of an acrylic block. PDC Soft Mark 3D marker is on the left and competitor marker is on the right. The slice is at the level of the block's top surface, where the markers are physically located. The dotted line shows the location of the perpendicular image of Figure 2.

x-z Plane View (Left: PDC Right: Competitor)



**Figure 2. Penetration of Marker Artifacts Through DBT Image:** Image perpendicular to the standard x-y plane DBT slices, showing the depth (top to bottom z-direction) penetration of artifacts from the PDC Soft Mark 3D marker (left side) and competitor marker (right side). The yellow dotted line at the top corresponds to the one in Figure 1, and is in the slice containing the markers at the top surface of the acrylic.

**Figure 3** is a plot comparing the intensities of the artifacts produced by the two markers in Figures 1 and 2. The horizontal axis shows the depth in millimeters below the markers themselves. The graph shows that the intensity of the PDC Soft Mark 3D marker artifacts (blue curve) is less than half that of the competitor marker (red curve) for all depths (all slices). This is consistent with the relative visual brightness of the artifacts shown in Figure 2.

In order to assess the impact of marker artifact visibility in a more clinically realistic setting, a human observer study was performed. The study used a phantom that is designed for 3D DBT imaging, and has a heterogeneous (non-uniform) background to simulate the structure of breast tissue. The phantom is designed so that sets of objects that simulate relevant structures in mammography (specks simulating microcalcifications, fibers simulating spiculations, and masses simulating breast masses) can be placed at various depths within the phantom. Markers were placed on the top surface of the phantom. Four different marker locations on the surface were evaluated; PDC and competitor markers were tested at each location. Imaging was performed using the acquisition settings selected by the DBT system’s automatic exposure control.

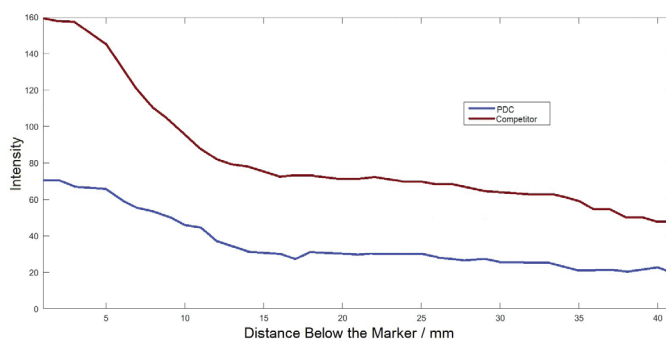
Seven readers (observers) participated in the study. Each reader was active in medical imaging research, as a faculty member, graduate student, or upper level undergraduate. Readers were blinded to the identities and locations of the markers prior to viewing the images. Each reader was asked to answer the following two questions:

1. For each marker what is the deepest slice in which the marker’s artifact is still visible (i.e. is just barely visible above the structure of the phantom background)?
2. In the slice containing the objects, how does the intensity of each object compare with that of the nearest artifact?

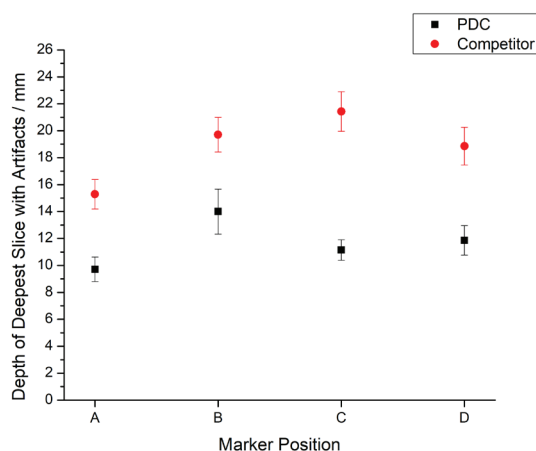
Question 2 above was answered using a 5-point scale as follows:

- 1: Artifact much less visible
- 2: Artifact somewhat less visible
- 3: Artifact and object about equally visible
- 4: Artifact somewhat more visible
- 5: Artifact much more visible

**Figure 4** shows the reader results for Question 1. The plotted points are the average of the results of seven readers, with the error bars denoting the standard deviations. For each of the four positions tested, the artifacts of the competitor marker are still visible at almost twice the depth of those of the PDC Soft Mark 3D marker. Thus approximately twice as many slices are affected by artifacts from the competitor marker compared to the PDC Soft Mark 3D marker.

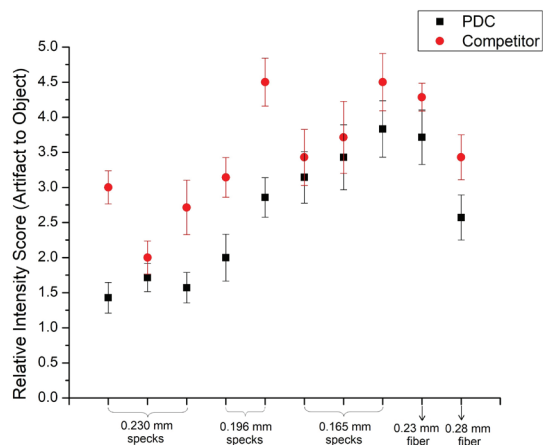


**Figure 3.** Plot showing the intensities of the artifacts associated with the two marker images shown in Figure 1. The horizontal axis shows the depth in millimeters below the markers, and the vertical axis shows artifact intensity. PDC = blue curve; Competitor = red curve



**Figure 4.** Deepest Slice in Which the Marker Artifacts are Visible. Each slice is 1 millimeter thick. Slice 0 is in the plane of the markers, at the top surface of the phantom.

**Figure 5** shows the reader scores when comparing the visual intensity of the marker artifacts to those of each of 10 objects in the phantom. Eight specks and two fibers were evaluated. Of the specks, three had diameters of 0.230 mm, two had diameters of 0.196 mm, and three had diameters of 0.165 mm. The two fibers had widths of 0.23 mm and 0.28 mm respectively. The graph symbols denote the average scores of the seven readers, and the error bars denote the standard deviations of the scores among all readers. The graph shows that for all objects the PDC Soft Mark 3D marker artifacts were scored as less visible than the competitor marker artifacts.



**Figure 5. Visual Intensity of Marker Artifacts Relative to the Embedded Objects.** Each artifact/object comparison was scored according to the following scale: 1. artifact much less visible; 2. artifact somewhat less visible; 3. artifact and object about equally visible; 4. artifact somewhat more visible; 5. artifact much more visible

## Summary

Skin marker selection can be critical to properly interpreting DBT images, and not all markers marketed for DBT are the same. Skin markers that are less attenuating, limit marker artifacts to fewer slices, and thus can potentially minimize the likelihood of missed abnormalities, and reduce artificial biasing of the attenuations (brightness in the image) of both normal and abnormal tissues in the breast. When choosing a DBT mammography skin marker, it is important that facilities implement ones that are specifically optimized for DBT so that the advantages of 3D multiple slice imaging are maximized.

Citations: Sharpe, R.E., Jr., Venkataraman, S., Phillips, J., Dialani, V., Fein-Zachary, VJ., Prakash, S., Slanetz, PJ., and Mehta, T.S. (2016). Increased Cancer Detection Rate and Variations in the Recall Rate Resulting from Implementation of 3D Digital Breast Tomosynthesis into a Population-based Screening Program. *Radiology* 278, 698–706.